



CLINICAL PRACTICE GUIDELINE

Guideline coverage includes NICU KEMH, NICU PMH and NETS WA

Cardiac: Coarctation of the Aorta (CoA) Management Following Surgical Repair

This document should be read in conjunction with the [Disclaimer](#)

This guideline focuses on the specifics of the post-op management and complications of a neonate following repair of a coarctation of the aorta.

For general post-op management and complications please refer to

- [Cardiac: Routine Post-Operative Care](#).
- [Cardiac: General Complications Management Following Surgery](#).
- For general information on Coarctation of the Aorta and pre-operative management refer to [Cardiac: Coarctation of the Aorta \(CoA\) and Interrupted Aortic Arch \(IAA\)](#).

Overview

Babies who have been diagnosed with CoA will have been commenced on a prostaglandin E1 infusion to reopen or keep open the ductus arteriosus. The coarctation itself is often responsive to PGE1, and so also commonly opens up. The baby will have been resuscitated as necessary and hopefully, if present, the acidosis resolved.

The post-operative course depends largely upon the baby's pre-operative condition. Those babies who were asymptomatic pre-operatively will most likely run a relatively benign post-operative course weaning from ventilation within 12-24 hours. Those who were unwell pre-operatively with acidosis/shock will most likely take a longer time to recover due to LV dysfunction, renal impairment and gut hypoperfusion.

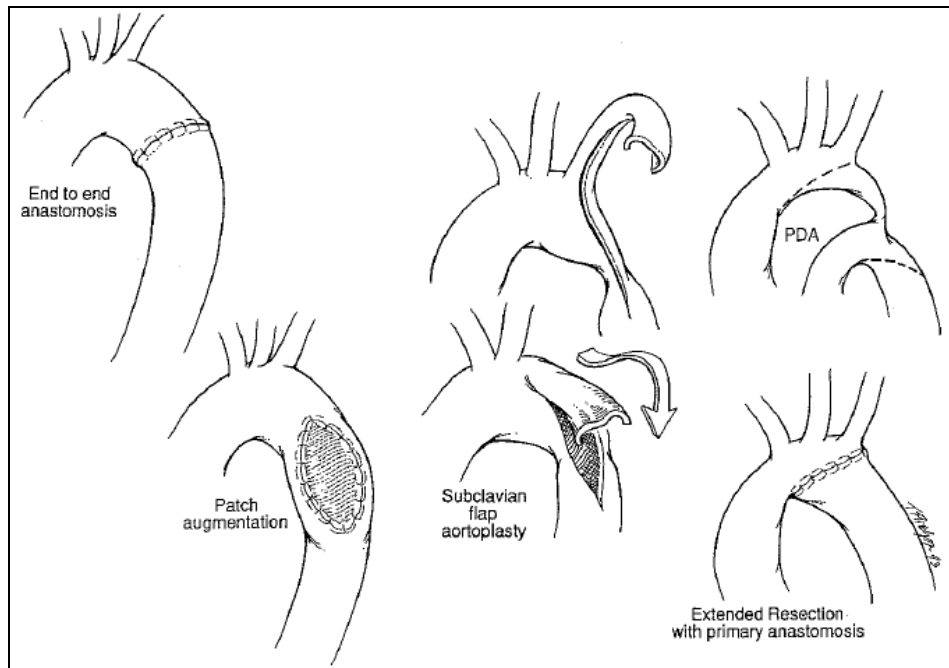
Surgical Procedure

The objective of surgical treatment is relief from aortic obstruction with minimal risk of repeat stenosis. Overall operative mortality is reported as around 7% in infants (lower in isolated CoA, higher in CoA + VSD and even higher when associated with more complicated intracardiac lesions).

Most procedures are closed cardiac cases (no cardiopulmonary bypass (CPB)) and the left thoracotomy approach is used. The aorta is cross-clamped for the period of the repair. When for instance, a VSD also needs repairing then a median sternotomy and CPB may be required.

There are 4 Main Operative Procedures Commonly Used in Repair of CoA

1. Resection of stenotic site and end-to-end anastomosis.
2. Extended resection with primary end-to-end anastomosis.
3. Subclavian flap aortoplasty.
4. Prosthetic patch augmentation.



Resection of Stenotic Site and End-To-End Anastomosis and Extended Resection with Primary End-To-End Anastomosis

The most common repair used is resection with end-to-end anastomosis. It has the advantage of removing all the ductal tissue from the repair site and preserving the subclavian artery.

Unfortunately many neonates have some degree of hypoplasia of the aortic arch, and simple resection and end-to-end anastomosis may not be sufficient. In this case a modified procedure called an extended resection with end-to-end anastomosis may be required. This involves end-to-side anastomosis of the descending aorta to a separate incision extended onto the underside of the aortic arch, proximal to the hypoplastic segment.

Subclavian Flap Aortoplasty

The subclavian flap repair uses the ipsilateral subclavian artery as a fold down flap to enlarge the coarctation site. This potentially allows growth of the repaired segment. This technique requires obligatory sacrifice of the subclavian artery. There is an inability to correct arch hypoplasia and a constant risk of limb ischaemia. Consequently this technique is used with diminishing frequency.

Prosthetic Patch Augmentation

A longitudinal incision opens the coarcted segment, which is then covered with a Dacron (polyester) or Goretex (PTFE) patch. This technique avoids extensive resection with possible risk of sacrificing of intercostal collaterals. However, long-term follow-up has shown a risk of development of aneurysm in the aortic wall opposite the graft. Avoidance of resection of the intimal ridge at the site of the coarctation and the use of a Goretex patch seems to have eliminated that risk and so remains a viable option. It has the advantage that it can be performed without ligating the ductus arteriosus and has been reported to be used successfully in cases where there is LV hypoplasia.

Routine Post-Op Management of Neonates Following Repair of CoA

For more general post-op cardiac management, refer to [Cardiac: Routine Post-Operative Care](#).

Respiratory

- Ventilation at least overnight before consideration of weaning.
- Normal neonatal ventilation strategy.
- Keep PCO₂ and SpO₂ within normal range.

CVS

- An invasive BP monitoring line should be in the right arm (pre-CoA). Cuff sphygmomanometry is useful and should be done in the other limbs to indicate adequacy of repair.
- The femoral pulses should be felt initially and then again whenever assessing the baby for any concerns and particularly if there is a metabolic acidosis or rising lactate.
- If inotropic support of LV required, dopamine 1st line and adrenaline 2nd line.
- Maintain mean BP below 60 mmHg firstly with adequate analgesia and if that is insufficient then consider if the patient may be fluid overloaded in which case give Frusemide and if that doesn't work, then lowering the BP with sodium nitroprusside (SNP) may be necessary (discuss with consultant). If this is inadequate, then an IV β -blocker (e.g. Labetolol) may need to be added (only if there is good LV function and at discretion of consultant). Refer to [Cardiac: General Complications Management Following Surgery](#) for Hypertension.
- Post-op echo should be performed and documented in the notes by cardiology within 1 hour of arrival back on NICU to assess the repair and LV function.

Fluids/Renal

- Commence 60-80 mL/kg/d 10% glucose/0.18% saline + potassium as required.
- Increase fluid allowance daily by 10-20 mL/kg/d depending upon clinical condition of patient.
- Maintain careful fluid balance. Be cautious of too much fluid as boluses in those with LV dysfunction particularly where there is pulmonary oedema.
- Regular diuretics (Frusemide and Spironolactone) may be required from day 2 post-op and weaned over a few days.

Gastrointestinal

- No feeds on first post-op day due to risk of NEC.
- Depending upon pre-op status, feeds may be commenced cautiously at least 24 hours post-op depending upon how sick the baby was pre-op (at discretion of consultant in charge).
- In the term baby feeds should be commenced at 5 mL 3 hourly and increased by 5 mL 6 hourly unless otherwise ordered by consultant in charge.
- If there are any signs of feed intolerance (e.g. Large aspirates/green or bloody aspirates) the baby should be medically reviewed and assessed for NEC and the feeds should be withheld for a further period before trying to re-commence once again (timing determined by consultant).

- Babies who have been/ are expected to be NBM for > 48 hours should have TPN commenced.

Antibiotics

- As per [Cardiac: Routine Post-Operative Care](#) guideline.

Analgesia/Sedation

- Morphine as per [Cardiac: Routine Post-Operative Care](#) guideline. Midazolam is seldom required in neonates and if used beware hypotensive effect.

Complications Following Repair of CoA

Respiratory

- Pulmonary hypertension (PHT) particularly in those with an associated VSD who may have a reactive pulmonary circulation. Treat with inhaled NO.
- Pulmonary oedema in those who have had pre-op cardiac failure may still be apparent and is initially treated with ventilation and careful fluid balance, and later diuretics.

Cardiovascular

- Ongoing left ventricular dysfunction and failure is often apparent in those babies who have presented in shock with severe acidosis pre-op. The LV may need to be supported with inotropes e.g. Dopamine for a few days whilst it recovers.
- Systemic hypertension is unusual in neonates, but if present is important to correct to protect the anastomosis and prevent bleeding at the site, prevent worsening LV function and cardiac failure, prevent postcoarctectomy syndrome (see below) and prevent CNS bleeds. It is usually due to the release of Catecholamines and renin at the time of cross-clamping of the aorta. The mean arterial pressure should be maintained in the normal range for age i.e. Below a mean of 60 mmHg. It should be treated with adequate pain relief, diuretics if patient deemed fluid overloaded and if these measures fail to make a difference SNP. Occasionally a β -blocker is required also (only where there is good LV function). The hypertension usually settles over a short period.

GI/Nutrition

- Ileus is common following reperfusion to the once underperfused gut. Feeds should be delayed until at least > 24 hours post-op (depends on how sick the baby was pre-op and commencement should be ordered by the treating consultant) and then introduced slowly and with caution. Early or aggressive feeding increases the risk of necrotizing enterocolitis (NEC).

Renal

- Renal dysfunction is common following repair, due to pre-op ischaemia of the kidneys secondary to hypoperfusion. Vigilant fluid balance is essential. The kidney function usually improves over a few days. Requirement of renal replacement therapy is rare.

Others

(For management refer to [Cardiac: General Complications Management Following Surgery](#)).

- Haemorrhage caused by anastomotic leak.
- Cylothorax caused by damage to the thoracic duct.

- Diaphragmatic palsy caused by phrenic nerve injury.
- Stridor and respiratory distress due to unilateral vocal cord paralysis caused by recurrent laryngeal nerve palsy.
- Spinal cord injury and paralysis due to prolonged aortic clamping (rare in neonates).
- Re-stenosis.
- Aneurysm at repair site (mainly following patch aortoplasty).
- Ischaemia of arm following subclavian flap repair, though temperature difference and slight impairment of growth and strength more common.

Postcoarctectomy Syndrome

Postcoarctectomy syndrome is very rare in neonates. It is well described in older children and consists of severe abdominal pain, hypertension, fever, abdominal tenderness, vomiting, ileus, melaena and leucocytosis. It occurs 2-3 days following surgery. It has been suggested that the sudden increase in blood pressure to the vessels below the CoA causes postcoarctectomy syndrome. There is resulting arteritis of the small arteries of the mesentery and small intestine. Alternatively, high renin levels post-op may cause shunting of the blood away from the mesenteric vessels. The changes are reversible and are treated and/or prevented by control of post-op hypertension.

Angioplasty

Angioplasty remains controversial for the primary treatment of native coarctation as the rates of recoarctation seem to be high especially in neonates.

However, balloon angioplasty is the treatment of choice for recoarctation following primary surgical repair. Recently stenting of the recoarctation has also been done.

References

1. Artman, M., Mahony, L., & Teitel, D. F. (2011). *Neonatal Cardiology* (Second ed.). USA.
2. Duncan, A., & Croston, E. (2008). *Guidelines for the Intensive Care Management of Infants and Children after Congenital Heart Surgery*. Paediatric Intensive Care Unit, Princess Margaret Hospital for children, Perth.
3. Horrox, F. (2002). *Manual of Neonatal and Paediatric Heart Disease* (First ed.). Gateshead, Tyne and Wear, UK: Whurr Publishers.
4. Koenig, P., Hijazi, Z. M., & Zimmerman, F. (2004). *Essential Pediatric Cardiology* (First ed.). USA: McGraw-Hill Companies, Inc.
5. Nichols, D. G., Ungerleider, R. M., Spevak, P. J., Greeley, W. J., Cameron, D. E., Lappe, D. G., & Wetzel, R. C. (2006). *Critical Heart Disease in Infants and Children* (Second ed.). USA: Mosby.




Related WNHS policies, procedures and guidelines

Neonatology Clinical Guideline - [Cardiac: Coarctation of the Aorta \(CoA\) and Interrupted Aortic Arch \(IAA\)](#)

Neonatology Clinical Guideline - [Cardiac: Routine Post-Operative Care](#)

Neonatology Clinical Guideline - [Cardiac: General Complications Management Following Surgery](#)

Cardiac: Coarctation of the Aorta (CoA) Management Following Surgical Repair

Document owner:	Neonatal Coordinating Group		
Author / Reviewer:	Neonatal Coordinating Group		
Date first issued:	May 2013		
Last reviewed:	1 st May 2013	Next review date:	1 st May 2016
Endorsed by:	Neonatal Coordinating Group	Date endorsed:	
Standards Applicable:	NSQHS Standards: 1  Governance, 6  Clinical Handover, 9  Clinical Deterioration		
Printed or personally saved electronic copies of this document are considered uncontrolled. Access the current version from the WNHS website.			