



## CLINICAL PRACTICE GUIDELINE

Guideline coverage includes NICU KEMH, NICU PCH and NETS WA

# Malrotation/Volvulus of the Intestines

This document should be read in conjunction with the [Disclaimer](#)

Malrotation is a congenital condition of the gut with serious, potentially fatal sequelae. The malrotated gut is prone to volvulus resulting in bowel obstruction and gangrene secondary to occlusion of the branches of the mesenteric artery. Intestinal obstruction due to malrotation can also result because of congenital fibrous (Ladd's) bands.

60-80% of all cases of malrotation present in the first month of life, mostly in the first week.

### Key Points

- Any **bilious vomiting or aspirates** is an important sign of malrotation and must be promptly investigated.
- Normal abdominal examination, AXR, lactate levels, blood pressure, urine output, blood gases do not rule out early intestinal gangrene secondary to malrotation/volvulus.
- Gold standard for investigating a suspected malrotation is Upper GI contrast study.
- Ultrasound of the abdomen is NOT a substitute for upper GI contrast, but can be used as the initial line of investigation in critically ill very preterm infants, who are too unstable to undergo contrast study. Close collaboration with the surgeons and radiologists is essential in such situations.

### Clinical Presentation

- Bilious vomiting must be promptly investigated even if the abdomen is soft and non-tender.
- Presence of distended tender/non tender abdomen in any neonate should prompt an investigation to rule out malrotation/volvulus irrespective of the presence or absence of vomiting.
- Bilious aspirates in premature infants <30-32 week can be due to dysmotility and be more difficult to interpret and definitively investigate in a small sick baby; Consultant staff must always be aware of the presence of bile stained aspirates in these babies. Preterm infants with persistent bilious aspirates should raise the suspicion of malrotation necessitating investigation.
- Presence of chylous fluid in an inguinal hernia sac during inguinal hernia repair should alert the surgeon and the neonatologists to the possibility of associated malrotation.

## Investigations and Management

Clinical judgement and prompt discussion with the surgeons is essential in an unwell infant with a distended abdomen. Once a diagnosis of malrotation and or volvulus is confirmed, the infant should be reviewed by the surgeon as soon as possible with a view to urgent laparotomy.

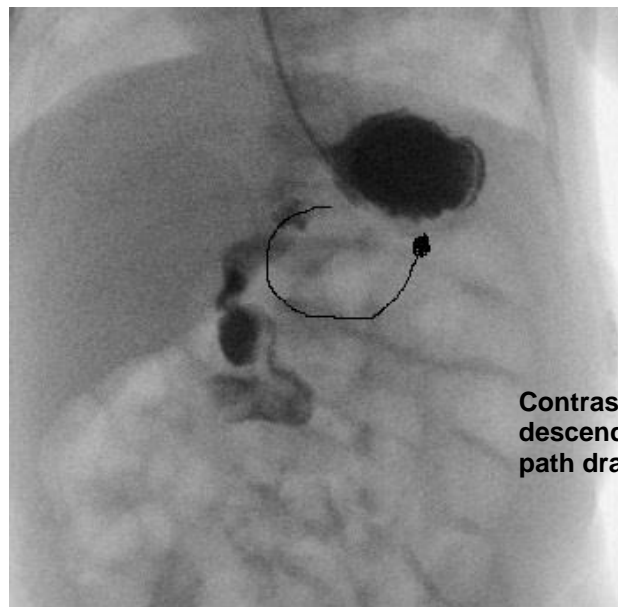
- Keep baby nil by mouth.
- Insert a large bore naso/orogastric tube; keep the tube on open drainage.
- Collect blood for sepsis screen, blood gas, glucose and blood group.
- Start IV Fluids and IV antibiotics (Penicillin, Gentamicin and Metronidazole).
- Assess if resuscitation fluids are required.

## Radiological Investigations

Plain X-ray of the abdomen is often non-specific. Dilatation of multiple loops of bowel on plain X-ray can signify volvulus with gut ischemia. Obtain both antero-posterior and lateral decubitus view of abdomen to rule out any gas under diaphragm.

The gold standard imaging test for diagnosing malrotation is an **upper GI contrast study** which shows an abnormal duodenum and duodenojejunal (DJ) flexure position. This is an emergency investigation and should not be deferred for any reason, even in otherwise well infants. The normal position of the DJ flexure is to the left of the spine and at the same level or higher than the duodenal bulb. Liaise with on call radiological consultant/registrar for arranging upper GI contrast study.

Although ultrasound of the abdomen is NOT a substitute for upper GI contrast, it can be useful in a critically ill preterm infant, who are too unstable to undergo contrast study. The ultrasound can show the orientation of the superior mesenteric vessels or the presence of a volved, ischemic mass.



Contrast exits stomach and descends instead of following the path drawn.

## Surgical and Post-Operative Management

Ladd's procedure.

Post-operative management includes analgesia (morphine), moderate maintenance fluid restriction (SIADH risk), monitor intake-output chart. Check the position of endotracheal tube with a chest X-ray if the infant returns to the NICU with a new ETT. Every infant should have a blood gas, electrolytes and FBC (and coagulation profile if indicated) soon after return to the NICU.


- Continue antibiotics.
- Refer to [General Post-Operative Care](#) guideline.
- Check the surgeon's orders on the Operation Theatre Notes.
- Discuss with the neonatal consultant.

## References

1. Applegate KE, Anderson JM, Klatte EC. Intestinal malrotation in children: a problem-solving approach to the upper gastrointestinal series. *Radiographics*. 2006 Sep-Oct;26(5):1485-500.
2. Applegate KE. Evidence-based diagnosis of malrotation and volvulus. *Pediatr Radiol*. 2009 Apr;39 Suppl 2:S161-3.
3. Chao HC, Kong MS, Chen JY, Lin SJ, Lin JN. Sonographic features related to volvulus in neonatal intestinal malrotation. *J Ultrasound Med*. 2000 Jun;19(6):371-6.
4. Danse EM, Kartheuser A, Paterson HM, Laterre PF. Color Doppler sonography of small bowel wall changes in 21 consecutive cases of acute mesenteric ischemia. *JBR-BTR*. 2009 Jul-Aug;92(4):202-6.
5. Kumar N, Curry JI. Bile-stained vomiting in the infant: green is not good! *Arch Dis Child Educ Pract Ed*. 2008 Jun;93(3):84-6.
6. Millar AJ, Rode H, Cywes S. Malrotation and volvulus in infancy and childhood. *Semin Pediatr Surg*. 2003 Nov;12(4):229-36.
7. Williams H. Green for danger! Intestinal malrotation and volvulus. *Arch Dis Child Educ Pract Ed*. 2007 Jun;92(3):ep87-91.
8. Zarroug AE, Srinivasan SK, Wulkan ML. Incidental chylous fluid during hernia repair may be a harbinger of malrotation. *J Pediatr Surg*. 2010 Jan;45(1):E17-8.

## Related WNHS policies, procedures and guidelines

Neonatal Clinical Guideline - [Post-Operative Care](#)

Document owner:	Neonatal Directorate Management Committee		
Author / Reviewer:	Neonatal Directorate Management Committee		
Date first issued:	June 2010		
Last reviewed:	1 <sup>st</sup> August 2018	Next review date:	1 <sup>st</sup> August 2021
Endorsed by:	Neonatal Directorate Management Committee	Date endorsed:	28 <sup>th</sup> August 2018
Standards Applicable:	NSQHS Standards: 1  Governance		

**Printed or personally saved electronic copies of this document are considered uncontrolled.  
Access the current version from the WNHS website.**