



## CLINICAL PRACTICE GUIDELINE

Guideline coverage includes NICU KEMH, NICU PMH and NETS WA

# Cardiac: Coarctation of the Aorta (CoA) and Interrupted Aortic Arch (IAA)

This document should be read in conjunction with the [Disclaimer](#)

Coarctation of the aorta accounts for 6-12% of all congenital heart disease and has an incidence of approx. 1 in every 1200-1300. It is more common in males in a ratio of 2:1.

Interrupted aortic arch (IAA) is rare, accounting for only 1% of critically ill neonates with congenital heart disease. The clinical presentation is similar to that of CoA, so is discussed here.

### Coarctation of the Aorta (CoA)

CoA is defined as a constriction or narrowing of the aorta which is variable in severity. It becomes significant when there is a pressure gradient of > 20 mmHg across the aortic narrowing. > 60% of infants have an associated bicuspid valve (of note, only a small proportion with a bicuspid aortic valve have a CoA) and in about 50% there are other associated lesions such as VSD, ASD, PDA, HLHS, TGA, mitral valve abnormalities, aortic stenosis.

CoA usually occurs in the thoracic aorta around the ductus, but rarely, it occurs in the abdominal aorta. It results from thickening of the media of the aortic wall that forms a ridge on the inner surface of the aorta. There is often post-stenotic dilatation of the descending aorta, but if the stenosis is severe, there may be hypoplasia of the proximal descending aorta, often referred to as long segment coarctation. There may also be narrowing of the transverse and isthmic portion of the aortic arch known as a hypoplastic arch.

### Classification of CoA

There are several classifications of CoA, the most useful is to divide the condition into pre- and post-ductal CoA, which classifies the blood flow of the anomaly.

**Pre-ductal** - The CoA is found proximal to the ductus arteriosus. It is frequently associated with other anomalies

**Post-ductal (Juxtaductal)** - This is the most common form and is found distal to the ductus arteriosus.

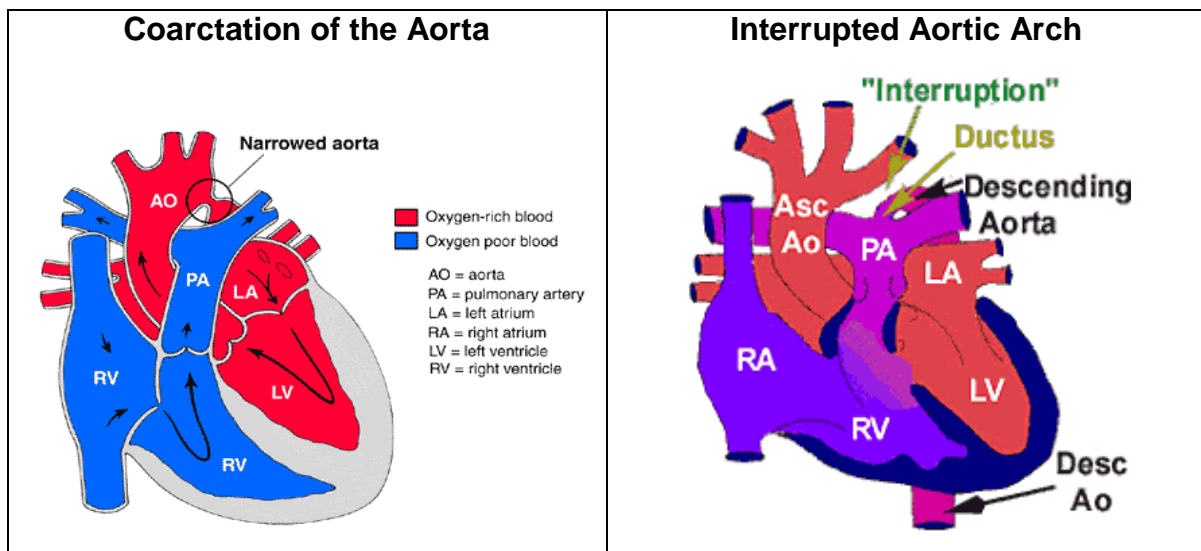
Another way to classify CoA is:

1. Isolated CoA.
2. CoA with VSD.
3. CoA with complicated intracardiac anomaly.

### Interrupted Aortic Arch (IAA)

Interrupted aortic arch consists of complete discontinuity between the 2 parts of the aortic arch, and in almost all cases is associated with a VSD and PDA. It can also be

associated with a bicuspid valve, mitral valve abnormality, truncus arteriosus and sub-aortic stenosis.



### Physiology of the Lesion

Narrowing in the aorta leads to decreased pressure or hypotension distal to the obstruction causing decreased perfusion of major organs and muscle. Decreased perfusion of the kidneys causes them to secrete renin which causes arterial vasoconstriction in an attempt to raise the distal pressure and so causing hypertension proximal to the obstruction. The left ventricle is subjected to increased pressure (afterload) which may lead to significant hypertrophy. With an acute increase the afterload, the left ventricle may not be able to compensate and clinical heart failure may occur. If this occurs, blood pressure may be decreased both proximally and distally to the obstruction.

In the presence of complete or near complete juxtaductal obstruction and a patent ductus arteriosus in the presence of raised PVR blood can still flow to the distal aorta (as is the case with neonates). This occurs by R→L shunting across the ductus to supply the abdominal organs and lower extremities. Therefore, blood flowing to the distal aorta will be desaturated.

If the obstruction is long-standing (those that present out of the neonatal period), collateral vessels develop from the proximal to the obstruction.

### Clinical Presentation

There are 2 distinct presentations: firstly in the neonatal period and secondly in infancy, childhood or adulthood. Only neonatal presentation will be dealt with here.

When CoA presents in the neonatal period, it is most often severe. They are usually asymptomatic at birth and become symptomatic as the ductus arteriosus closes at 4-10 days age. The neonate has been receiving desaturated blood to the lower extremities until this time but this provides adequate perfusion to the abdominal organs and lower extremities. Occasionally, a murmur of a PDA or VSD is heard at the physical check which leads to further investigations, but usually, symptoms first present when the ductus begins to close or when there is associated LV failure.

The initial symptoms may be decreased feeding, abbreviated feeds with shortness of breath and sweating or vomiting due to poor gut perfusion. As the duct shuts, shock ensues.

### Clinical Signs

- Grey/mottled appearance.

- Lethargic/decreased level consciousness.
- Prolonged capillary refill in lower extremities.
- Absent femoral pulses (full pulses in right arm).
- Differential blood pressure between lower extremities and right arm.
- Tachypnoea/recessions.
- Differential in pre- and post-ductal SaO<sub>2</sub>.
- Enlarged liver.
- Oliguria/anuria.
- Metabolic acidosis (often severe).

### **Genetic/Syndromic Associations**

The exact genetic and molecular abnormality of this defect is unknown. However, CoA is frequently a component of several chromosomal abnormality syndromes. It is relatively common in trisomy 13 and 18. 15-20% of infants with Turner's Syndrome have CoA.

### **Management of CoA/IAA**

#### **Initial Management at Birth if Diagnosed Antenatally**

- Unlikely to be unwell at birth, so usual postnatal resuscitative measures.
- Admit to SCN3, assess and contact cardiologist early.
- Make arrangements for transfer to Ward 6B when stable and safe to do so.

#### **Management If Presenting Collapsed/Shocked**

##### **Airway/Breathing**

- Most likely will require mechanical ventilation (especially if transporting on PGE1 infusion).
- Use pressures/FiO<sub>2</sub> to keep normocarbida (though infant may hyperventilate and ↓pCO<sub>2</sub> to compensate for metabolic acidosis). Monitor SaO<sub>2</sub> in right hand, maintain 94-97%.

##### **Circulation**

- Need good access (initial peripheral IV or UVC).
- Arterial line helpful but do not delay treatment for this. DO NOT use right radial or brachial arteries unless very confident of success as required for theatre.
- Give normal saline fluid boluses in aliquots, maximum of 10 mL/kg with each. Give up to 20 mL/kg total and if requiring more than this, discuss with consultant as may make cardiac failure worse.
- Commence PGE1/Alprostadil as soon as possible at 50ng/kg/min.
- Left ventricle may need support with inotropes. Start with dopamine 10 mcg/kg/min. (If no central access, Dobutamine up to 10 mcg/kg/min may be used peripherally, but watch infusion site carefully).

##### **In Addition**

- Give IV Amoxicillin and Gentamicin if sepsis possible.
- Use small amount of sedation for intubation and as ongoing infusion (50mcg/kg bolus flowed by 10mcg/kg/hr) so as not to compromise cardiac function further. Paralysis is not normally necessary or desirable.
- Maintain normothermia and normoglycaemia.

- Consider other causes shock:
  - Sepsis.
  - Other cardiac disease.
  - Metabolic disease.
  - Intra-abdominal pathology such as volvulus.
  - Causes of bleeding such as trauma/NAI/Vit K deficiency.
  - Communicate with NETS WA/cardiology early.

### Investigations

- **Blood Gas** - If presenting in shock, may show severe metabolic/ lactic acidosis which may be partially compensated with a low pCO<sub>2</sub>.
- **Routine Bloods:**
  - **FBC** - should have normal Hb, platelets may be ↓ if period of hypoperfusion/shock.
  - **Coagulation profiles** - may be deranged (particularly INR) if period hypoperfusion/ shock.
  - **U+E** - electrolytes should be normal, but creatinine may be elevated if period of hypoperfusion/ shock.
  - **LFTs** - transaminases may be elevated if period hypoperfusion/shock.
  - **Ca/Mg** - any infant in shock or when 22q11 deletion possible (e.g. IAA). Ionised Ca on gas most helpful.
  - **CRP** - check for evidence sepsis.
  - **Blood culture** - if sepsis possible.
  - **G+H**
- **Chromosomal analysis** - if dysmorphic features/other anomalies and send for 22q11 deletion if IAA.
- **CXR** - May show cardiomegaly and ↑ pulmonary vascular markings secondary to heart failure. Check position of tubes/lines.
- **Echo** - Diagnosis can usually be confirmed with cardiac echo. The prominent features are a narrowed aortic segment at the site of the CoA and post-stenotic dilatation of the descending aorta. Doppler is used across the defect to determine the pressure gradient. Occasionally the CoA is not visualised as the PGE1 has opened up the CoA itself. Echo also determines other associated defects, whether there is adequate flow through the PDA and the function of the left ventricle.
- **Cranial USS** - Particularly for those who present unwell should be preferably be performed prior to theatre.
- **Renal USS** - If there are other anomalies/chromosomal abnormality suspected.

### Ongoing Preoperative Management

#### CVS

- Continue PGE1/Alprostadil until theatre. The dose may be decreased to 25ng/kg/min on the advice of the cardiologist.
- Femoral pulses should be assessed regularly once PGE1 infusion commenced until palpated, then reassessed at change of shift or if clinical concerns over the patient.

- The lactate level should be followed closely:  
Hourly initially until patient stabilising and metabolic acidosis improving.
  - Then 2 hourly until metabolic acidosis/lactate normalised.
  - Then 4 hourly unless clinical deterioration.
  - If lactate it is not improving or starts rising, femorals should be felt and consultant +/- cardiologist informed.
  - BP mean should be kept > 45mmHg (unless otherwise stated by consultant or cardiologist).
  - Inotropic support of the heart is commonly required as there is often LV dysfunction. First choice is dopamine 10-20mcg/kg/min. If a further inotrope is required, then Adrenaline or Milrinone may be considered.

### Respiratory

Most patients having presented collapsed/ in shock will be mechanically ventilated.

- Normal SIPPV+VG with normal term neonatal settings for PEEP and pressures should be used. A higher PEEP may be required if there are signs of pulmonary oedema.
- Patient should be ventilated to normocarbica (though as mentioned before, may breath up to hypocarbica to compensate for metabolic acidosis until it has resolved).
- The minimum FiO<sub>2</sub> to keep the pre-ductal O<sub>2</sub> sats 94-97% should be used.

### Fluids/Nutrition

- The patient should be fluid restricted and total volume will depend upon postnatal age. In a patient > 4 days old, 80 mL/kg/day 10% Dextrose + 0.22% Saline should be used (with potassium added as required) initially and liberalised depending upon the clinical status of the patient.
- Further saline boluses are sometimes required, but should be used judiciously and only 5mL/kg at a time with reassessment prior to further.
- Watch electrolytes closely, particularly K and Ca and correct accordingly.
- The patient should be NBM prior to theatre as there is a very high risk of NEC due to prolonged hypoperfusion of the gut and the following reperfusion injury.
- These patients are going to be NBM for some days, so TPN should be initiated early.
- Urine output should be recorded hourly and should be >1mL/kg/hr. A urinary catheter will most likely be required.
- Sometimes Frusemide is necessary especially in heart failure and to assist urine output.

### Sepsis

As sepsis is common in neonates, and not to be missed, most will be given at least 48 hours IV amoxicillin and gentamicin until cultures are back.

### Haematology

Correct coagulopathy/ low platelet count as necessary.

### Neuro

- Sedation with low dose morphine is usually all that is required.
- Muscle relaxation is rarely required or desired.

## Lines

- All patients having presented in shock require a central line (UVC or CVC) and arterial line (UAC or peripheral).
- The right upper limb arteries should be avoided if at all possible unless the operator is extremely confident of success (and then only one of the arteries should be tried) as a line here is required by the anaesthetist for theatre.

## Possible Pre-Operative Complications

- Renal impairment/ failure.
- Cardiac failure.
- Coagulopathy.
- Multiorgan failure.
- Necrotising enterocolitis.

## Usual Operative Management/Treatment Options

Operative repair is usually carried out once the acidosis and multiorgan failure have settled.

Refer to Neonatology Clinical Guidelines

- [Cardiac: Coarctation of the Aorta \(CoA\) Management Following Surgical Closure](#)
- [Cardiac: Routine Post-Operative Care](#)
- [Cardiac: General Complications Management Following Surgery.](#)

## References

1. Nichols, D.G.; Ungerleider, R.M.; Spevak, P.J.; Greeley, W.J.; Cameron, D.E.; Lappe, D.G.; Wetzel, R.C., *Critical heart disease in infants and children*. Second ed.; Mosby: USA, 2006.
2. Artman, M.; Mahony, L.; Teitel, D.F., *Neonatal cardiology*. Second ed.; USA, 2011.
3. Horrox, F., *Manual of neonatal and paediatric heart disease*. First ed.; Whurr Publishers: Gateshead, Tyne and Wear, UK, 2002.
4. Koenig, P.; Hijazi, Z.M.; Zimmerman, F., *Essential pediatric cardiology*. First ed.; McGraw-Hill Companies, Inc: USA, 2004




## Related WNHS policies, procedures and guidelines

Neonatology Clinical Guideline - [Cardiac: Coarctation of the Aorta \(CoA\) Management Following Surgical Closure](#)

Neonatology Clinical Guideline - [Cardiac: Routine Post-Operative Care](#)

Neonatology Clinical Guideline - [Cardiac: General Complications Management Following Surgery](#)

Cardiac: Coarctation of the Aorta (CoA) and Interrupted Aortic Arch (IAA)

Document owner:	Neonatal Coordinating Group		
Author / Reviewer:	Neonatal Coordinating Group		
Date first issued:	April 2014		
Last reviewed:	1 <sup>st</sup> September 2015	Next review date:	1 <sup>st</sup> September 2018
Endorsed by:	Neonatal Coordinating Group	Date endorsed:	September 2015
Standards Applicable:	NSQHS Standards: 1  Governance, 6  Clinical Handover, 9  Clinical Deterioration		
<b>Printed or personally saved electronic copies of this document are considered uncontrolled.                  Access the current version from the WNHS website.</b>			